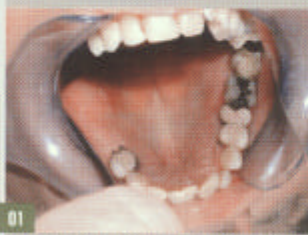
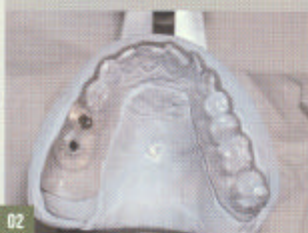
Sinus lift and modified transfer system

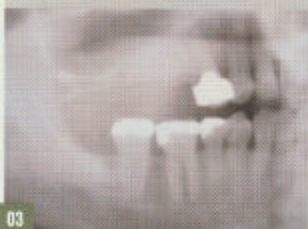The treatment of a shortened row of teeth in the right maxilla using two ITI implants



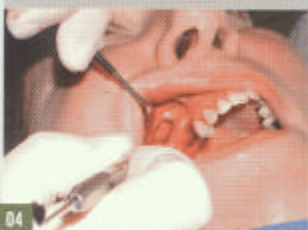01 Shortened row of teeth in the right maxilla



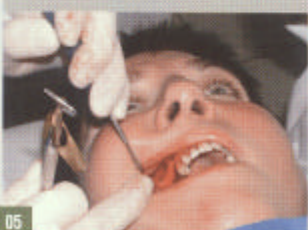02 Drill template with titanium sleeves



03 Initial OPG



04 Local access to the sinus cavity



05 Augmentation in the posterior region of the sinus cavity

In many practices and among many patients, implantology still leads a shadow existence today for many reasons.

On the one hand, patients think that this is exclusive high-tech medicine, which is reserved for only a small circle of people, and on the other hand, the argument is heard from many practices that: "I don't have the right clientele for it." Neither is correct, as the following case shows:

The requirement of the legal health insurance companies of "satisfactory, effective, economical", often leads to results that restore mastication in a more or less simple manner, without giving attention to the individual expectations and needs of the patients.

In this case, the shortened row of teeth in the right lateral maxilla had been treated with a removable denture. [fig. 1] The patient, for lack of information about alternatives, had accepted the situation despite the poorly tolerated transverse band. When she learned in a casual conversation that modern implant prosthetics would enable her to have fixed

dental replacements again, she decided spontaneously on this treatment, which commenced a short time later.

After a model analysis, a wax-up was first produced and this was transferred to a drill template with titanium sleeves. [fig. 2]

The X-ray [fig. 3] shows advanced pneumatisation of the maxillary sinus. However, the remaining bone height suggested that if an open sinus lift operation were performed at the same time it should be possible to insert two ITI solid screw implants with good primary stability.

Access to the sinus cavity was created through a vestibular window [fig. 4], and the Schneiderian membrane was elevated carefully to make space for the implants.

Using the drilling template, the positions previously established in the model were transferred to the jaw and the bone cavities were prepared in ascending order up to 3.5 mm.

Attention should be paid particularly to sparing the Schneiderian membrane, so

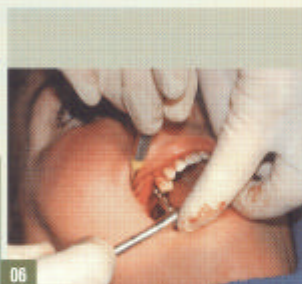
that no large perforation occurs.

First, the posterior part of the sinus cavity, which is no longer accessible after insertion of the implants, was filled with an augmentation complex of Cerasorb, blood from the defect and PRP (platelet-rich plasma). [fig. 5]

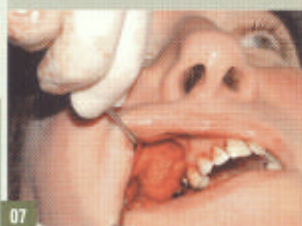Both implants were then screwed in [fig. 6], achieving very good primary stability as expected. The defect could be closed after the anterior part of the sinus cavity was filled with the Cerasorb-/PRP complex. [fig. 7] The highly stable shape of this complex with an intact mucoperiosteal flap allowed wound closure without additional use of a membrane. [fig. 8] Healing was completely complication-free, and it was even possible to do without further medications.

Four months later, the OPG showed early ossification in the augmentation region [fig. 9], so that it was possible to produce a long-term temporary crown for the purpose of progressive bone loading.

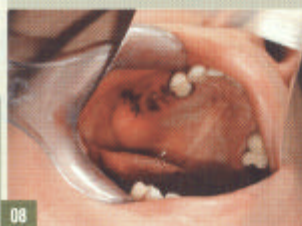When the solid abutments were tried on, it was apparent that the height of 4.0 mm was somewhat too short and the height of 5.5 mm was somewhat too long. [fig. 10] Usually, only the 5.5 mm height would be selected and shortened in the mouth. However, the advantages of exact transfer offered by the ITI® DENTAL IMPLANT SYSTEM would be lost.



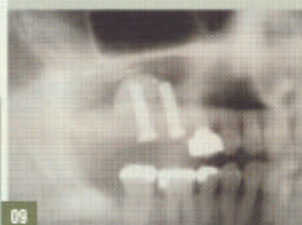06 Inserting the implants



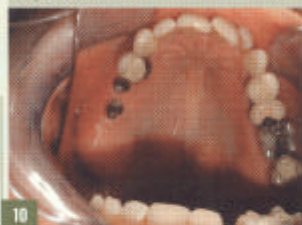07 The finished augmented sinus cavity



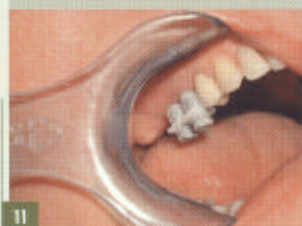08 Situation after wound closure



09 OPG after 4 months, early ossification



10 Trying the solid abutments



11 The ITI transfer system

The procedure was as follows:
Exact transfer with impression caps and positioning cylinder was undertaken using the 5.5 mm height. [fig. 11]

In the laboratory, the corresponding colour-coded analogues were now inserted [fig. 12], a model was made and articulated into the correct bite situation.

The required degree of shortening could then be determined by analysing the model. Copings of pattern resin were put on and coded with black lines so that they would not be confused later in the mouth. [fig. 13]

The analogues including resin copings could now be shortened to the length that gave an optimum interocclusal distance. At the same time, a coded key was used to transfer the shortening exactly to the mouth situation. [fig. 15]

The long-term temporary crowns were then manufactured on the shortened solid abutments and delivered to the practice. The interdental spaces were kept open to allow optimum hygiene. [fig. 16]

After trying and examining the accuracy of fit, the long-term temporary crown was incorporated. The patient could be treated with a fixed dental prosthesis after a relatively short time to her complete satisfaction. The resistance to abrasion

and stability of the Artglass crowns do not necessitate manufacture of a definitive work. [fig. 17]

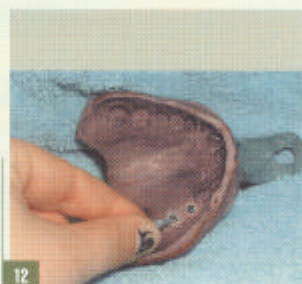Summary

In this case, it was possible to incorporate a denture after a period of only four months despite a residual bone height of approx. 5 mm and an open sinus lift. This is considerably shorter than the times that have been usual hitherto with such operations. There may well be a synergistic effect between the Cerasorb-/PRP treatment complex and the SLA surface of the ITI implants, which leads overall to faster healing. The ITI transfer system with impression cap and positioning cylinder allows the mouth situation to be transferred exactly to the model and back to the mouth in modified form with the transfer key. A further advantage is that the definitive restoration can also be made on the same models.

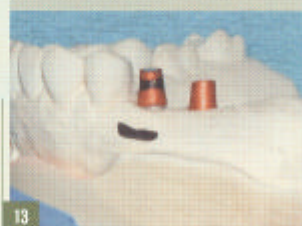Address for correspondence:

Dieter Bilk
Dentist
Ober-Hörgener-Str. 7
D-35516 Münzenberg
Tel: +49-60 33-6 34 73

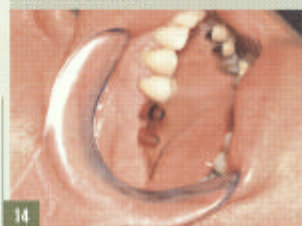LP Dental Technique
ZTM Reiner Pauli
Raiffeisenstraße 9
D-61250 Usingen
Tel: +49-60 81-1 43 80



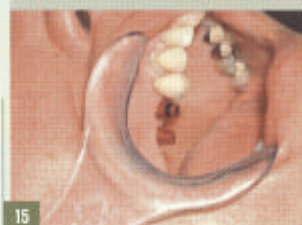12 Inserting the analogues



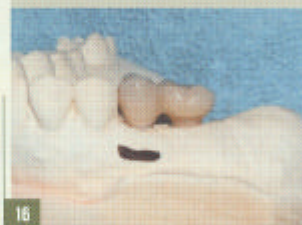13 The copings of pattern resin, coded and shortened



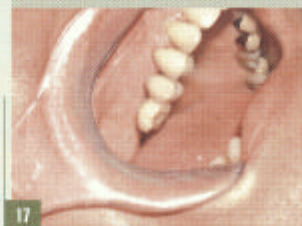14 The coded copings in the mouth



15 The reduced solid abutments



16 The finished work on the model



17 The finished work in the mouth